Small Animal Clinic - Surgery[1], Division of Veterinary Anatomy[2], Veterinary student[3], Institute of Animal Pathology[4] and Division of Clinical Radiology[5], Vetsuisse Faculty of Berne, Switzerland

Palpation accuracy of thoracolumbar spinous processes using T13 and the 13th pair of ribs as landmarks in dogs

F.L. NOUSSITOU[1], S. FORTERRE[1], M.H. STOFFEL[2], M. GROCCIA[3], K. HAAS[3], F. BRUSA[3], J. HOWARD[4], D. GORGAS[5] and F. FORTERRE[1]*

received July 2, 2016
accepted January 21, 2017

Keywords: palpation accuracy, localization, thoracolumbar, spinous process.

Summary

There is a lack of studies of methods for the clinical assessment of spinal orientation in dogs. Our objective was to determine the accuracy of the identification of the thoracolumbar spinous process by palpation using T13 and the associated pair of ribs. We wished to assess whether spinal localization can be accurately determined by this method and whether the accuracy depends on examiner experience and variables linked to dog characteristics. Four examiners identified different thoracolumbar spinous processes in 120 dogs using one-hand palpation of the T13 spinous process and the 13th pair of ribs. The spinous process (T13, L1 or L2) was marked with a hypodermic needle and a laterolateral radiograph or a postoperative ventrodorsal radiograph of the thoracolumbar spine was performed to confirm the vertebral determination. The relationship of accuracy to length of the examiner's fingers, training level and the body condition score of the dogs (BCS) were determined. Identification was correct in 87.5% of the cases. All the defined vertebrae were identified with no difference in accuracy (p=0.89). There was no difference between individual examiners (p=0.26). The size of hand had no influence (p=0.13). There was a statistically significant association between the palpatory accuracy and a BCS of 5 (OR=21.11; 95% CI 1.08 – 5.02; p=0.003), as well as with the factor of an experienced examiner in dogs with a BCS of 5 (OR=5.76; 95% CI 0.14 – 3.36; p=0.019). Considering the whole study population, the palpatory accuracy of detecting the thoracolumbar spinous process using T13 and the 13th pair of ribs seems to be independent of examiner experience. In neurosurgical cases the authors recommend confirming the findings by means of diagnostic imaging.

*E-mail: fiammetta.noussitou@vetsuisse.unibe.ch

Schlüsselwörter: Genauigkeit der Palpation, Lokalisation, thorakolumbar, *Processus spinosus*.

Zusammenfassung

Genauigkeit der Palpation von T13 mit Orientierungshilfe des *Processus spinosus* T13 und des 13. Rippenpaares beim Hund

Einleitung

Studien, welche die klinischen Orientierungsmethoden an der Wirbelsäule von Hunden beschreiben, fehlen. Unser Ziel war es, die Präzision der Identifikation des *Processus spinosus* durch Palpation von T13 und dem assoziierten Rippenpaar zu bestimmen. Unsere Hypothese war, dass die spinale Lokalisation mit dieser Methode genau bestimmt werden kann und der Erfolg von der Erfahrung des Untersuchers und von den charakteristischen Variablen des Hundes unabhängig ist.

Material und Methoden

Vier Untersucher ermittelten an 120 Hunden unterschiedliche thorakolumbare Dornfortsätze mittels einer Einhand-Palpationstechnik des *Processus spinosus* von T13 und des 13. Rippenpaares. Der zu bestimmende Dornfortsatz (T13, L1 oder L2) wurde mit einer Injektionsnadel markiert und eine lateralolaterale Röntgenaufnahme oder eine postoperative ventrodorsale Röntgenaufnahme der thorakolumbalen Wirbelsäule durchgeführt, um die Richtigkeit des ermittelten Wirbelkörpers zu bestätigen. Das Verhältnis zwischen Treffsicherheit und der Fingerlänge des Untersuchers, dem Erfahrungsniveau und dem Nährzustand (Body Condition Score) der Hunde wurden bestimmt.

Ergebnisse

Korrekte Identifikationen traten in 87,5% auf. Alle festgelegten Wirbel wurden ohne Unterschiede in Genauigkeit bestimmt (p=0,89). Es gab keine

Unterschiede zwischen den einzelnen Untersuchern (p=0,26). Die Grösse der Hand hatte keinen Einfluss (p=0,13). Eine statistisch signifikante Korrelation wurde zwischen der Präzision der Palpation und einem BCS von 5 (OR=21,11; 95% CI 1,08–5,02; p=0,003), sowie dem Erfahrungsgrad des Untersuchers bei Hunden mit einem BCS von 5 festgestellt (OR=5,76; 95% CI 0,14–3,36; p=0,019).

Schlussfolgerung

Die Genauigkeit der Palpation von thorakolumbalen Dornforsätzen mit Hilfe von T13 und dem 13. Rippenpaar scheint unabhängig vom Erfahrungswert des Untersuchers zu sein. In neurochirurgischen Fällen empfehlen die Autoren diese Methode in Kombination mit bildgebenden Verfahren einzusetzen.

Introduction

Accurate localization of vertebrae in dogs is important for the interpretation of the findings of neurological examinations and critical in spinal surgery, lumbar epidural injection, lumbar Cerebrospinal fluid taps and myelography. Anatomic landmarks described for vertebral localization include the spinous process of the anticlinal vertebra; the distance between the transverse process of the first lumbar vertebra and the head of the last rib; and the relationship of the spinous process of the sixth lumbar vertebra to the wings of the ilium (SHARP and WHEELER, 2005; FRANCH and LOPEZ, 2007). Despite these descriptions, fluoroscopy, radiography and computed tomography are frequently used to confirm the precise localization prior to spinal surgery or injections. In contrast to the case in human medicine, there is a lack of studies of clinical methods for spinal orientation and their validity in dogs (SNIDER et al., 2011).

The objective of the study was to determine the accuracy of identification of lumbar vertebrae using palpation of T13 and the 13th pair of ribs as bony landmarks and to assess the effect of examiner experience, hand size and dog characteristics, such as body condition scores and gender, on the accuracy of the results. We hoped that an accurate determination of spinal localization would be possible with this method and that the accuracy would be independent of examiner experience and variables linked to dog characteristics.

Material und methods

Animals

Dogs presented at our institution for orthopaedic and/or thoracolumbar neurosurgical conditions necessitating hemilaminectomy were recruited for the study over a twelve-month period. Dogs were excluded if they presented with dorsal trunk neoplasms or a history of vertebral trauma that could interfere with the accuracy of palpation. Breed, age, gender and body weight were recorded. In addition, a body condition score (BCS) was assessed by a single examiner (FF) and scored as 1 (very thin), 2 (thin), 3 (ideal), 4 (10 to 20% over the ideal body weight), or 5 (>40% over the ideal body weight) (EDNEY and SMITH, 1986). The study was approved by the local ethics institution. A signed form for informed client consent from the owners was required for enrolment to the study.

Examiners

Dogs were examined by four right-handed examiners: one board-certified senior surgeon specialized in neurosurgery (FF) and three fourth-year students of veterinary medicine (MG, KH, FB). Each student examined 20 dogs presented with orthopaedic problems requiring sedation for skeletal radiographs. Palpation and localization of T13 were performed under sedation. The senior surgeon used the same techniques to examine 60 dogs with thoracolumbar disc extrusion under general anaesthesia immediately prior to surgery.

The length of the right thumb and index and middle fingers, from the wrist to the tip of the finger, was measured in all examiners using callipers. The ratio of lengths of the index to middle finger was calculated for each examiner. Hand size was arbitrarily classified, based on the length of the middle finger, as small (<16 cm), medium (16–18 cm) or large (>18 cm).

T13 identification

Location of the spinous process of T13 was performed as follows. The dogs were examined in ventral recumbency with the examiner standing on the left of the dog with the sagittal plane of the examiner's body parallel to the dog's body. With the fingers of the right hand in semi-extension, the tips of the thumb and middle finger were positioned on the caudal aspect of the left and right 13th rib. This was performed on the most ventral part of the ribs that allowed contact of the index finger with a spinous process using slight flexion of the wrist (see Fig. 1). The spinous process thus identified was considered to be T13 and was confirmed as such by palpation of the caudal adjacent spinous process of L1, which is wider than T13.

Using this method, each student was asked to localize a predetermined vertebra (T13, L1 or L2) in each dog. They were asked to label the vertebra of interest by inserting a sterile 23G cannula on the sagittal midpoint of the tip of the spinous process. A laterolateral radiograph was used to identify correct or incorrect localization. For neurosurgical patients with thoracolumbar disc extrusion at the intervertebral spaces T12-T13, T13-L1 and L1-2, the surgical site was identified using the same manual localization of T13 and counting the spinous processes to the site of the lesion previously determined using MRI. Correct localization of the surgical site was evaluated using postoperative ventrodorsal radiographs of the spine. Prior to the study, students familiarized themselves with the method on a midsize canine skeleton.

Assessment of radiographs

All radiographs were reviewed to determine the accuracy of needle placement over the spinous process and postoperative images. Only needle placement directly on the predetermined spinous process was defined as accurate. The site of hemilaminectomy was recorded for neurosurgical patients. The radiographs were also assessed for evidence of congenital anomalies that might affect the accuracy of palpation, such as block or wedge vertebrae, rudimentary or agenesis of the 13th ribs or floating ribs.

Statistical analysis

Statistical analysis was performed with commercial software (NCSS 2007, NCSS, LLC. Kaysville, Utah, USA. www.ncss.com and MedCalc version 15.8, MedCalc Software, Ostend, Belgium). Normality of continuous data was evaluated using D'Agostino-Pearson's test and by examining Q-Q plots. Fisher's exact test was used to evaluate associations between categorical data. A Kruskal-Wallis test was used to evaluate associations between continuous and categorical data. The impact of age, sex, body weight, BCS and examiner experience (senior author with more than 20 years of clinical experience vs 4th year students) on accuracy of localization were further evaluated using logistic regression. Significance was set at $p<0.05$ throughout.

Results

Examiner's hand size

The index-to-middle finger ratio was similar for all examiners, with values ranging between 0.94 and 0.95. The size of the examiners' hands were classified as small (two students), medium (surgeon) and large (one student).

Dogs

In total, 120 dogs were enrolled in the study. Breeds represented by at least five dogs were crossbreed (n=19), Dachshund (n=14), French bulldog (n=14), German shepherd (n=10), Yorkshire terrier (n=8) and Jack Russell terrier (n=5). The median body weight at presentation was 13.0 kg (range 1.0–70.0 kg). There were 69 males (42 intact, 27 castrated) and 51 females (24 intact, 27 spayed). The median age at presentation was 6.0 years (range 0.2–13.0). The body condition was scored as BCS 2 in 32 dogs, BCS 3 in 52 dogs, BCS 4 in 25 dogs and BCS 5 in 11 dogs. There was no significant difference in BCS scores related to gender (p=0.868), age (p=0.472) or reproductive status (intact or castrated) (p=0.937).

Accuracy of palpation

Correct localization was achieved in 87.5% (105 dogs) of examinations. In 13 dogs, incorrect localization occurred on the adjacent cranial (n=4) or caudal (n=9) vertebra; in two dogs, localization was two vertebrae cranial (n=1) or caudal (n=1) to the target vertebra. No difference was found in accuracy of localization between the different vertebrae (T13, L1, L2) (p=0.890).

Effect of examiner on palpation accuracy

Vertebra were correctly localized by students in 80–85% of cases and by the surgeon in 93% of the cases but no difference between examiners was found (p=0.170). Although greater experience (surgeon versus student) was associated with greater accuracy, the difference was not statistically significant (p=0.095). Hand size had no influence on accuracy of palpation (p=0.103).

Effect of dog characteristics on palpation accuracy

No significant difference in accuracy of palpation was found due to gender (p=0.411), age (p=0.830), reproductive status (p=0.097) or body weight (p=0.069), although the median weight of dogs with an incorrect localization was higher than that of those with the correct localization. However, a significant difference was found for BCS (p<0.001) (see Fig. 2). Anatomic abnormalities were present in six neurosurgical dogs (5%) that had a rib anomaly detected on MRI. No dog in the orthopaedic group was affected, so the condition was not sufficient frequent to enable its effect on accuracy to be assessed.

Tab. 1: Palpation accuracy of thoracolumbar spinous processes using T13 and the 13th pair of ribs as landmarks in dogs based on examiner, hand size and body condition score / Genauigkeit der Palpation von T13 mit Orientierungshilfe des *Processus spinosus* T13 und des 13. Rippenpaares beim Hund in Abhängigkeit von Untersucher, Handgröße und Ernährungszustand

Variable	Classification	Palpation accuracy		p value
		Correct [n (%)]	Incorrect [n (%)]	
All cases		105 (87.5%)	15 (12.5%)	
Examiner	Student 1	16 (80.0%)	4 (20.0%)	
	Student 2	16 (80.0%)	4 (20.0%)	
	Student 3	17 (85.0%)	3 (15.0%)	0.170
	Surgeon	56 (93.3%)	4 (06.7%)	
Hand size	Small	32 (80.0%)	8 (20.0%)	
	Medium	56 (93.3%)	4 (06.7%)	0.103
	Large	17 (85.0%)	3 (15.0%)	
Body condition score	BCS 2	29 (90.6%)	3 (09.4%)	
	BCS 3	50 (96.2%)	2 (03.8%)	
	BCS 4	21 (84.0%)	4 (16.0%)	<0.001
	BCS 5	5 (45.5%)	6 (54.5%)	

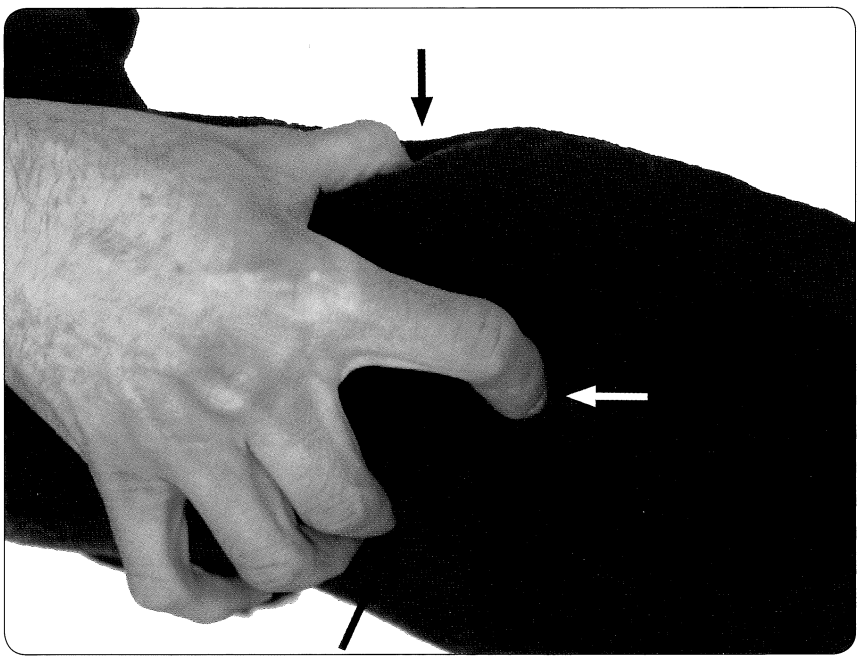

Fig. 1: Manual identification of T13. The fingers of the right hand are placed in semi-extension and the tips of the thumb and middle finger on the caudal aspect of the left and right 13th rib (black arrows). Slight flexion of the wrist allows the tip of the index finger to contact the spinous process of T13 (white arrow). / Manuelle Identifizierung von T13. Die Finger der rechten Hand sind in Halb-Extension, mit der Spitze des Daumens und des Mittelfingers über dem kaudalen Anteil der linken bzw. rechten 13. Rippe (schwarze Pfeile). Leichte Flexion des Handgelenks erlaubt es, mit der Spitze des Zeigfingers den *Processus spinosus* von T13 zu berühren (weisser Pfeil).

Regression analysis and odds ratios of variables affecting palpation accuracy

Entering all variables in a stepwise manner in logistic regression revealed that only a BCS of 5 ($p<0.001$) and low experience (student) ($p=0.019$) were associated with inaccurate localization, with odds ratios of 52 (95% CI, 6–484) and 13 (95% CI, 2–103), respectively.

Discussion

Exact anatomical orientation along the spine of dogs remains a clinical challenge. Various methods have been described in textbooks but there is a lack of studies of their accuracy (SHARP and WHEELER, 2005; TOBIAS and JOHNSTON, 2012). The one-handed method of T13 localization described in this study was associated with high accuracy (87.5%) but the clinical value of the result must be interpreted with caution as there have been no comparable studies in small animal medicine. Whether other techniques are superior can thus not be assessed. The percentage of erroneous localizations (± 1 vertebra) may be considered clinically irrelevant if the purpose of localization is to determine a clinical suspicion prior to confirmatory diagnostic imaging but may be unacceptable if localization is performed for surgical orientation. Other described surgical orientation techniques involve the identification of landmarks (last rib, transverse process of the first lumbar vertebra, thoracolumbar anticlinal vertebra, L6 and sacrum) and tissue labelling by injecting a dye (methylene blue) or inserting a marker needle under radiographic or fluoroscopic guidance (SHARP and WHEELER, 2005; FRANCH and LOPEZ, 2007).

Anatomic variation affecting vertebrae and ribs may affect localization by the technique described in this study. However, this point could not be evaluated as neither rudimentary nor floating ribs occurred in the dogs evaluated for orthopaedic reasons. Had malformations been present, the examiners would have been unaware of them prior to palpation and a greater number of incorrect localizations may have occurred. In neurosurgical cases, the examiner was aware of anomalies prior to palpation and localization was correct in all six cases. An increased or decreased number of lumbar vertebrae would not affect vertebra determination as the method uses the thoracolumbar junction as a landmark.

The present study revealed no difference between examiners in the accuracy of localization but low experience (students) was associated with a greater risk of incorrect localization. Given the difference between experienced and inexperienced examiners, this might suggest a type II error from a low case number in each of the inexperienced examiner's groups. However, the elevated odds ratio would be consistent with an examiner difference should more cases have been examined. One study in humans demonstrated greater accuracy in examiners with greater knowledge of anatomy (PHILLIPS et al., 2009). The present study was based on only three students and a single surgeon and the surgeon performed palpation on dogs after clipping the hair, which was not the case for the students. The greater contact with the bony landmarks may have facilitated palpation for the surgeon. Studies of the interobserver reliability of palpating specific vertebral segments in humans have shown variable results (BINKLEY et al., 1995; MCKENZIE and TAYLOR, 1997; BILLIS et al., 2003; SEFFINGER et al., 2004) but this point was not evaluated in the present study.

The size of the examiner's hands did not appear to influence the accuracy of localization. This may be because localization depends on both the index and the middle fingers. The ratio of the lengths of these fingers is very similar in people and independent of gender (MCFADDEN and SHUBEL, 2002). The similar relative lengths of the two fingers may permit examiners to reach the same bony markers regardless of hand size. A short thumb and middle finger of a small hand will be placed dorsal on the rib arch, allowing a short index finger to contact T13, while a long thumb and middle

finger of a large hand will be placed ventral on the rib arch, allowing a long index finger to reach the same point. It should be noted that only four examiners were included in this study and this number should be increased before any conclusions can be drawn.

An elevated BCS was associated with lower accuracy in our study. This finding corroborates reports of the difficulty in palpation of obese human patients (BROADBENT et al., 2000; EIDELMANN et al., 2005; STIFFLER et al., 2007). Subcutaneous tissue thickness in humans has been reported to be least at L1 and progressively greater at L5 (HARLICK et al., 2007). Although tissue depth was not specifically quantified in the current study, localization of T12 instead of T13 during practise with the canine skeleton underlines the impact of this factor on localization.

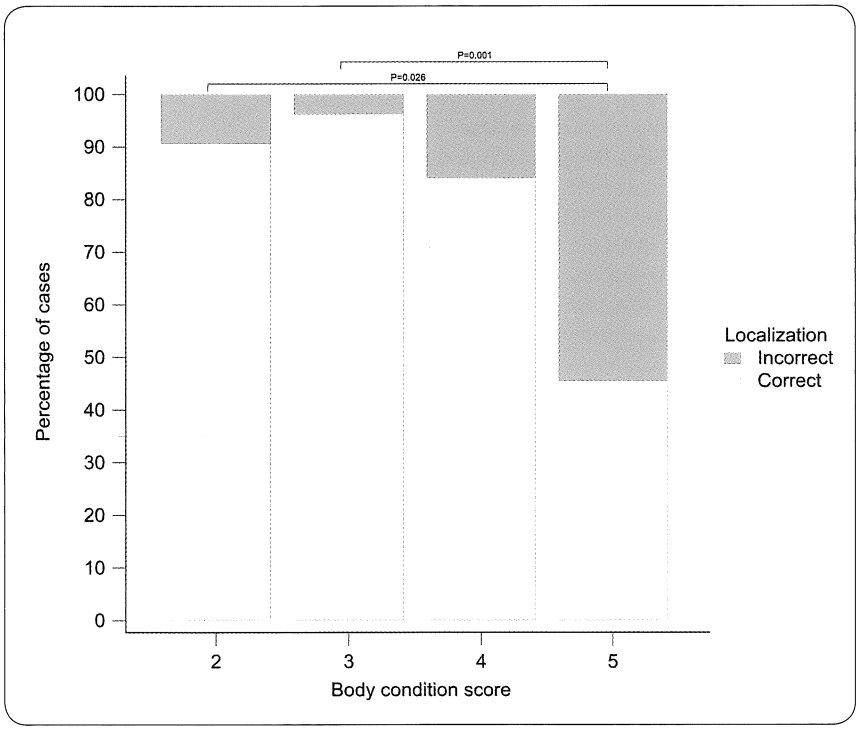

Fig. 2: Accuracy of palpation of thoracolumbar spinous processes in dogs with various body condition scores. A higher BCS elicited a significant decrease in palpation accuracy / Genauigkeit der Palpation von T13 bei Hunden mit untersciedlichem Body Condition Score. Ein höherer BCS rief eine signifikante Verminderung der Genauigkeit der Palpation hervor.

The size of the patients may also have influenced the accuracy of palpation but body weight was not associated with accuracy and localization was incorrect in dogs weighing from 3 to 52 kg. However, the number of incorrect localizations was too low to enable a precise evaluation of the effect of body weight.

The study suffers from several limitations. It limited the localization of vertebrae between T13 and L2. Only four examiners were evaluated and the use of a single experienced physician to determine the effect of examiner training and experience does not allow conclusions relating to examiners in general. A further limitation was that different examiners studied different groups of dogs, making it impossible to evaluate inter-observer reliability. Furthermore the surgeon was guided by the MRI results of the dogs with regard to the presence of vertebral or rib anomalies, whereas students assessed the dogs without imaging. To exclude vertebral anomalies, orthogonal radiographs would have been preferable to a single laterolateral radiograph of the vertebral column. Assessment of the neurosurgical cases with a post-operative ventrodorsal spinal radiograph was not uniform with regard to the technique used for confirming the localization of the orthopedic cases. Given that the neurosurgical cases had the benefit of a surgical approach and direct palpation of anatomic landmarks, the localization would ideally have been performed preoperatively with a cannula. The inclusion of multiple examiners with varying levels of experience and separately assessing each dog would have improved the study design. The study did not include any left-handed examiners. An assessment of the possible influence of hand size requires further studies on a larger number of examiners with different hand sizes. Further studies are also necessary to evaluate inter- and intra-observer reliability. Although findings showed a high level of accuracy, incorrect localization was observed in some cases regardless of experience. In particular, patient obesity negatively impacts the accuracy of localization. Correct anatomical localization is essential to avert spinal cord injury during surgical procedures. In consequence, fluoroscopy, radiography or computed tomography are recommended unless more accurate manual methods are devised.

Fazit für die Praxis:
Die Methode kann in der Praxis für eine grobe Lokalisation eines schmerzhaften Prozesses benutzt werden. Jedoch sollten weiterführenden bildgebenden Verfahren für eine genaue Lokalisation, z.B. für einen chirurgischen Zugang, zusätzlich angewendet werden. Insbesondere bei übergewichtigen Patienten kann sich diese Methode jedoch schwierig darstellen.

References

BILLIS, E.V., FOSTER, N.E., WRIGHT, C.C. (2003): Reproducibility and repeatability: errors of three groups of physiotherapists in locating spinal levels by palpation. Man Ther **8**, 223–232.

BINKLEY, J., STRATFORD, P.W., GILL, C. (1995): Interrater reliability of lumbar accessory motion mobility testing. Phys Ther **75**, 786–792.

BROADBENT, C.R., MAXWELL, W.B., FERRIE, R., WILSON, D.J., GAWNE-CAIN, M., RUSSELL, R. (2000): Ability of anaesthetists to identify a marked lumbar interspace. Anaesthesia **55**, 1122–1126.

EDNEY, A.T., SMITH, P.M. (1986): Study of obesity in dogs visiting veterinary practices in the United Kingdom. Vet Rec **118**, 391–396.

EIDELMANN, A., SHULMAN, M.S., NOVAK, G.M. (2005): Fluoroscopic imaging for technically difficult spinal anesthesia. J Clin Anest **17**, 69–71.

FRANCH, J., LOPEZ, C. (2007): Bilateraler dorsaler Zugang zu den thorakolumbalen Wirbeln. In: FRANCH, J., LOPEZ, C. (Eds): Atlas der chirurgischen Zugänge. Urban and Fischer, Munich, 146–148.

HARLICK, J.C., MILOSAVLJEVIC, S., MILBURN, P.D. (2007): Palpation identification of spinous processes in the lumbar spine. Man Ther **12**, 56–62.

MCFADDEN, D., SHUBEL, E. (2002): Relative lengths of fingers and toes in human males and females. Horm Behav **42**, 492–500.

MCKENZIE, A.M., TAYLOR, .N.F. (1997): Can physiotherapists locate lumbar spinal levels by palpation? Physiotherapy **83**, 235–239.

PHILLIPS, D.R., BARNARD, S., MULLEE, M.A., HURLEY, M.V. (2009): Simple anatomical information improves the accuracy of locating specific spinous processes during manual examination of the low back. Man Ther **14**, 346–350.

SEFFINGER, M.A., NAJM, W.I., MISHRA, S.I., ADAMS, A., DICKERSON, V.M., MURPHY, L.S., REINSCH, S. (2004): Reliability of spinal palpation for diagnosis of back and neck pain: a systematic review of the literature. Spine **29**, E413–425.

SHARP, N.J.W., WHEELER, S.J. (2005): Thoracolumbar disc disease. In: SHARP, N.J.W., WHEELER, S.J. (Eds).: Small animal spinal disorders Diagnosis and Surgery. 2nd ed., Elsevier Mosby, St. Louis, Missouri, 121–159.

SNIDER, K.T., SNIDER, E.J., DEGENHARDT, B.F., JOHNSON, J.C., KRIBS, J.W. (2011): Palpatory accuracy of lumbar spinous processes using multiple bony landmarks. J Manipulative Physiol Ther **34**, 306–313.

STIFFLER, K.A., JWAYYED, S., WILBER, S.T., ROBINSON, A. (2007): The use of ultrasound to identify pertinent landmarks for lumbar puncture. Am J Emerg Med **25**, 331–334.

TOBIAS, K.M.J., JOHNSTON, S.A. (2012): Thoracolumbar Spine. In: TOBIAS, K.M.J., JOHNSTON, S.A. (Eds): Veterinary surgery small animal. Saunders Elsevier, St. Louis, Missouri, 449–475.